



Australian and New Zealand College of Veterinary Scientists

Membership Examination

June 2017

Veterinary Radiology (Large Animal) Paper 1

Perusal time: **Fifteen (15)** minutes

Time allowed: **Two (2)** hours after perusal

Section A: Answer **ALL TWO (2)** questions

Section B: Answer **ALL FOUR (4)** questions

Section C: Answer **ALL TEN (10)** questions

Section C requires the completion of **ten (10)** multiple choice questions, located in the answer booklet that has been provided to you. *(Sample provided in this paper)*

© 2017 Australian and New Zealand College of Veterinary Scientists ABN 00 50 000894 208
This publication is copyright. Other than for the purposes of and subject to the conditions prescribed under the Copyright Act, no part of it may in any form or by any means (electronic, mechanical, microcopying, photocopying, recording or otherwise) be reproduced, stored in a retrieval system or transmitted without prior written permission. Enquiries should be addressed to the Australian and New Zealand College of Veterinary Scientists

Section A: **TWO** essay-type questions each worth 30 markstotal 60 marks

Section B: **FOUR** short-answer questions each worth 10 markstotal 40 marks

Section C: **TEN** multiple choice questions each worth 2 markstotal 20 marks

Paper 1: Veterinary Radiology (Large Animal)

SECTION A

Answer both questions in Section A

1. Answer **all** parts of this question:

- a) Define 'ionising radiation'. (2 marks)
- b) The X-ray photons produced by the X-ray tube have a range of energies.

Answer **both** parts of this sub-question:

- i. Explain the **two (2)** interactions that occur at the anode to produce X-ray photons. (12 marks)
 - ii. Explain the contribution of these interactions to the range of energies in the resultant beam of X-ray photons. (3 marks)
- c) List the **three (3)** potential outcomes of an X-ray photon when it reaches a patient. (3 marks)
- d) Explain why the photoelectric effect is important in the formation of a radiographic image. (5 marks)
- e) State the probability of a photoelectric effect occurring during X-ray exposure. (5 marks)

2. Answer **all** parts of this question:

- a) Discuss the major advantages and disadvantages of digital radiography (DR) versus film-screen radiography. (21 marks)
- b) Describe the process of image formation in computed radiography. (9 marks)

Section B over page

SECTION B

Answer all four (4) questions in Section B

1. Answer **both** parts of this question:

a) Explain the difference between an 'ionic iodinated contrast agent' and a 'non-ionic iodinated contrast agent'. (3 marks)

b) Answer **both** parts of this sub-question:

i. Name the contrast procedure used to investigate a draining sinus on the lateral aspect of the left radius on an adult horse. (1 mark)

ii. Describe how to perform this contrast procedure. (6 marks)

2. Answer **both** parts of this question:

a) Name the transducer type and frequency of the **two (2)** transducers that would be required to perform a complete sonographic examination of the palmar aspect of the metacarpus, the palmar aspect of the digit and the palmar aspect of the foot of an adult horse. (2 marks)

b) Compare and contrast the advantages **and** disadvantages of the transducers you selected in the above question. (8 marks)

Section B continued over page

3. Answer **both** parts of this question:
- a) Answer **both** parts of this sub-question:
 - i. Define MPD. *(1 mark)*
 - ii. Briefly explain the term MPD. *(3 marks)*
 - b) List the ancillary equipment required to acquire radiographs in the field of the distal limb of an adult horse following ‘as low as reasonably achievable’ (ALARA) principles of radiation safety. *(6 marks)*
4. Name **four (4)** radiographic projections to evaluate the nasal cavity in the horse. Briefly describe the structures assessed and the role of **each** projection in an adult horse with unilateral right nasal discharge. *(10 marks)*

Section C continued in provided answer booklet

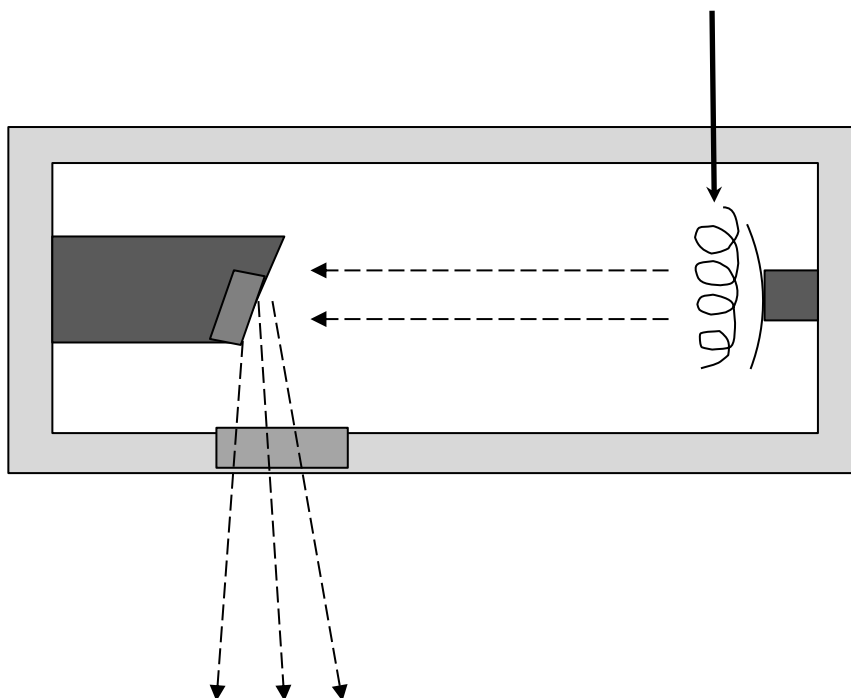
Paper 1: Veterinary Radiology (Large Animal)

Section C: Answer all ten (10) multiple choice questions in this section, on the printed pages 5 to 8, in this answer booklet.

Answer all ten (10) questions on the examination paper. This section is worth twenty (20) marks. Each question is worth two (2) marks. Circle the letter corresponding to your chosen answer. There is no negative marking.

(10 multiple choice questions will be part of this examination located in a separate answer booklet that will be provided. Two examples for each paper have been made available.)

1. In the diagram below, which of the following options is the correct name for the component of an X-ray tube indicated by the solid arrow? (2 marks)



- a. tungsten target
- b. anode
- c. tube port
- d. cathode filament

2. Which of the following actions can a radiographer take to reduce the amount of scatter radiation produced by a patient? (2 marks)
- a. collimate the beam
 - b. reduce mAs
 - c. use a grid
 - d. increase kVp

End of paper



Australian and New Zealand College of Veterinary Scientists

Membership Examination

June 2017

Veterinary Radiology (Large Animal) Paper 2

Perusal time: **Fifteen (15)** minutes

Time allowed: **Two (2)** hours after perusal

Section A: Answer **ALL TWO (2)** questions

Section B: Answer **ALL FOUR (4)** questions

Section C: Answer **ALL TEN (10)** questions

Section C is requires completion of **ten (10)** multiple choice questions located in the answer booklet that has been provided to you. *(Sample provided in this paper)*

© 2017 Australian and New Zealand College of Veterinary Scientists ABN 00 50 000894 208
This publication is copyright. Other than for the purposes of and subject to the conditions prescribed under the Copyright Act, no part of it may in any form or by any means (electronic, mechanical, microcopying, photocopying, recording or otherwise) be reproduced, stored in a retrieval system or transmitted without prior written permission. Enquiries should be addressed to the Australian and New Zealand College of Veterinary Scientists

Section A: **TWO** essay-type questions each worth 30 markstotal 60 marks

Section B: **FOUR** short-answer questions each worth 10 markstotal 40 marks

Section C: **TEN** multiple choice questions each worth 2 markstotal 20 marks

Paper 2: Veterinary Radiology (Large Animal)

SECTION A

Answer both questions in Section A

1. Answer **all** parts of this question:

- a) Describe the pathophysiology of osteochondrosis. *(15 marks)*
- b) List the joints in the horse that can be affected by osteochondrosis. State for **each** joint whether this is a common or uncommon location for osteochondrosis. *(5 marks)*
- c) List the specific locations of osteochondrosis lesions in the tarsus. Briefly describe the radiographic features at **each** site. *(10 marks)*

2. Answer **all** parts of this question:

- a) Describe the pathophysiology of ‘non-septic physitis’ and ‘septic physitis’. *(15 marks)*
- b) Name the radiographic projections which should be considered in a patient with non-septic physitis. List the most commonly affected physes. *(2 marks)*
- c) Describe the radiological features of non-septic physitis. *(13 marks)*

Section B over page

SECTION B

Answer all four (4) questions in Section B

1. A six-month-old alpaca cria presents with carpal valgus.

Answer **all** parts of this question:

- a) Briefly describe the radiographic features of angular limb deformity of the carpus. *(4 marks)*
- b) Describe how the radiographic features would differ if the underlying cause was vitamin D deficiency (rickets) *(4 marks)*
- c) List all the anatomical locations of the skeleton affected by vitamin D deficiency (rickets). *(2 marks)*

2. Answer **both** parts of this question:

- a) List **five (5)** ultrasonographic changes that can be seen in acute tendonitis of the superficial digital flexor tendon. *(5 marks)*
- b) List **five (5)** ultrasonographic changes that can be seen in chronic tendonitis of the superficial digital flexor tendon. *(5 marks)*

3. Answer **all** parts of this question:

- a) What is navicular disease/syndrome? *(1 mark)*
- b) List **six (6)** radiological changes that can be seen in navicular disease/syndrome. *(6 marks)*
- c) List **three (3)** radiographic projections that can be used to evaluate the navicular bone with a patient in a standing position. *(3 marks)*

Section B continued over page

4. Answer **both** parts of this question:

- a) List the regions of the small and large intestine that are accessible to transabdominal ultrasound in the adult horse. State the sonographic landmarks used to identify **each** of the regions listed. *(4 marks)*

- b) Briefly discuss the advantages of performing transthoracic ultrasound when compared to thoracic radiography in an adult horse with suspected pleuropneumonia. *(6 marks)*

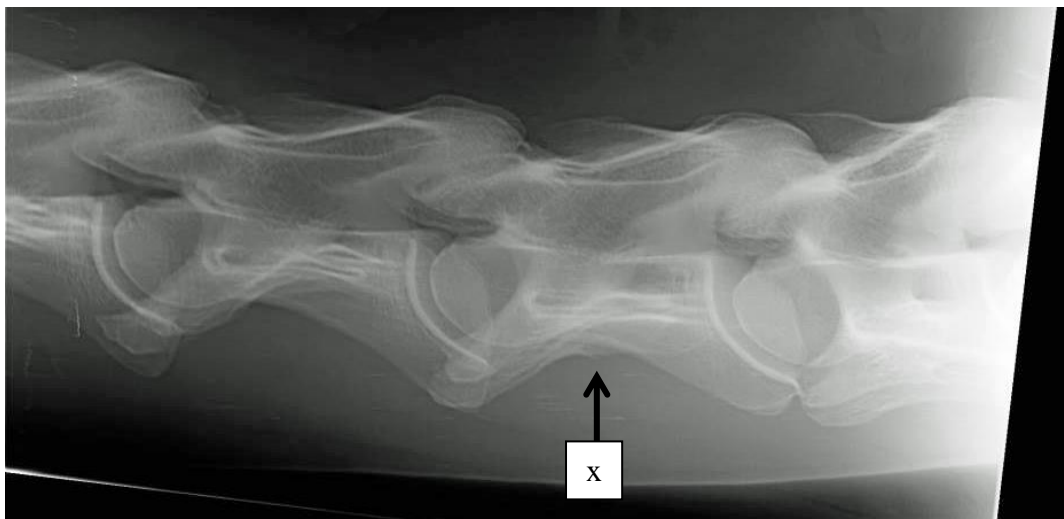
Section C continued in provided answer booklet

Paper 2: Veterinary Radiology (Large Animal)

Section C: Answer all ten (10) multiple choice questions in this section, on printed pages 5 to 8, in this answer booklet.

Answer all ten (10) questions on the examination paper. This section is worth twenty (20) marks. Each question is worth two (2) marks. Circle the letter corresponding to your chosen answer. There is no negative marking.

(10 multiple choice questions will be part of this examination located in a separate answer booklet that will be provided. Two examples for each paper have been made available.)



1. On the radiograph provided above the cervical vertebra labelled (x) is: (2 marks)
 - a. C4
 - b. C5
 - c. C6
 - d. C7

2. Which surface of the equine carpus will be projected in an unobstructed manner ('free projected') in a dorsolateral-palmaromedial radiograph? (2 marks)
 - a. Dorsomedial
 - b. Dorsolateral
 - c. Lateral
 - d. Dorsal

End of paper