



Australian and New Zealand College of Veterinary Scientists

Membership Examination

June 2015

Veterinary Radiology (Small Animal)

Paper 1

Perusal time: **Fifteen (15)** minutes

Time allowed: **Two (2)** hours after perusal

Section A: Answer **ALL TWO (2)** questions

Section B: Answer **ALL FOUR (4)** questions

Section C: Answer **ALL TEN (10)** questions

Section C is multiple choice which requires completion of **ten (10)** multiple choice questions located in the answer booklet you have been provided. *(Sample provided in this paper)*

© 2015 Australian and New Zealand College of Veterinary Scientists ABN 00 50 000894 208

This publication is copyright. Other than for the purposes of and subject to the conditions prescribed under the Copyright Act, no part of it may in any form or by any means (electronic, mechanical, microcopying, photocopying, recording or otherwise) be reproduced, stored in a retrieval system or transmitted without prior written permission. Enquiries should be addressed to the Australian and New Zealand College of Veterinary Scientists

Section A: **TWO** essay-type questions each worth 30 markstotal 60 marks

Section B: **FOUR** short-answer questions each worth 10 markstotal 40 marks

Section C: **TEN** multiple choice questions each worth 2 markstotal 20 marks

Paper 1: Veterinary Radiology (Small Animal)

SECTION A

Answer both questions in Section A

1. Answer **all** parts of this question:
 - a) Define radiographic image contrast. (2 marks)
 - b) List the features that contribute to radiographic image contrast. For **each** feature listed, indicate whether it occurs with film screen radiography (FSR), with digital radiography (DR), or both. (6 marks)
 - c) For **three (3)** of the features listed in 1 b) briefly describe how the veterinarian may increase radiographic image contrast. (6 marks)
 - d) Describe how a computed radiography (CR) system detects and produces a radiographic image. Your answer should include the following steps in the process: (16 marks)
 - i. image capture
 - ii. conversion to an electronic signal
 - iii. image processing and modification
 - iv. image display.

Continued over page

2. You have access to a portable ultrasound machine with a 12 MHz microconvex transducer and a 5 MHz microconvex transducer. You wish to assess the relative cardiac chamber sizes and contractility of a 50 kg dog's heart. The machine only has an 'abdominal' preset.

Answer **all** parts of this question:

- a) List **two (2)** machine controls you need to change from the 'abdominal' preset to optimise the image for echocardiology. *(2 marks)*
- b) For **each** of the **two (2)** machine controls listed in 2 a) discuss how **each** control alters the image when changing from the 'abdominal' preset to echocardiology. *(8 marks)*
- c) State which one of the two available transducers would be most appropriate to assess this patient's heart. Briefly discuss the physical properties of sound that lead to the advantages and disadvantages of using your chosen transducer. *(10 marks)*
- d) List **four (4)** other machine controls that may be altered during the examination. Briefly describe how **each** of these controls optimises the image. *(10 marks)*

Section B over page

SECTION B

Answer all four (4) questions in Section B

1. Answer **both** parts of this question:
 - a) Describe the structure and purpose of a grid when making a radiographic exposure. (3 marks)
 - b) Describe the structure of **three (3)** different types of grids. For **each**, briefly discuss their clinical advantages **and** limitations of their use. (7 marks)

2. Answer **all** parts of this question:
 - a) List **four (4)** examples of personal protective equipment (PPE) used in veterinary radiography. (2 marks)
 - b) Discuss the meaning of the term 'half value layer', with respect to PPE in veterinary radiography. (2 marks)
 - c) Discuss the use and limitations of PPE during a radiographic examination. (6 marks)

3. Answer **all** parts of this question:
 - a) Define the stochastic **and** deterministic effects of radiation. Which of these effects is most important in a clinical veterinary radiology setting? (4 marks)
 - b) Define the ALARA principle. (1 mark)
 - c) Describe how the ALARA principle may be practically applied in a clinical setting. (5 marks)

Continued over page

4. Answer **all** parts of this question:
- a) Describe the cause of the reverberation artefact seen during ultrasound examination of the normal thorax. (3 marks)
 - b) Describe the cause of the edge shadowing artefact seen during ultrasound examination of the kidney. (3 marks)
 - c) List an example of the origin of the 'dirty' shadow artefact seen during abdominal ultrasound **and** state how this artefact is formed. (2 marks)
 - d) List an example of the origin of the 'clean' shadow artefact seen during abdominal ultrasound **and** state how this artefact is formed. (2 marks)

Section C continued in provided answer booklet

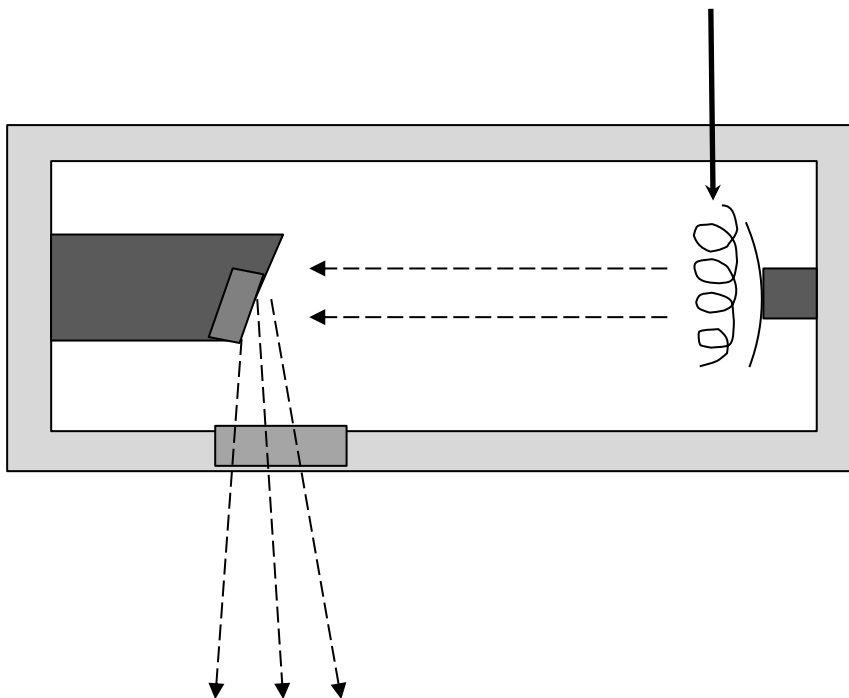
Paper 1: Veterinary Radiology (Small Animal)

Section C: Answer all ten (10) multiple choice questions in this section on printed pages 6 to 9 in this answer booklet.

Answer all ten (10) questions on the examination paper. This section is worth 20 marks. Each question is worth two (2) marks. Circle the letter corresponding to your chosen answer.

(10 multiple choice questions will be part of this examination located in a separate answer booklet that will be provided. Two examples for each paper have been made available.)

1. In the diagram below, which of the following options is the correct name for the component of an x-ray tube indicated by the solid arrow? (2 marks)



- a) tungsten target
- b) anode
- c) tube port
- d) cathode filament

2. Which of the following actions can a radiographer take to reduce the amount of scatter radiation produced by a patient? (2 marks)
- a) collimate the beam
 - b) reduce mAs
 - c) use a grid
 - d) increase kVp

End of paper



Australian and New Zealand College of Veterinary Scientists

Membership Examination

June 2015

Veterinary Radiology (Small Animal)

Paper 2

Perusal time: **Fifteen (15)** minutes

Time allowed: **Two (2)** hours after perusal

Section A: Answer **ALL TWO (2)** questions

Section B: Answer **ALL FOUR (4)** questions

Section C: Answer **ALL TEN (10)** questions

Section C is multiple choice which requires completion of **ten (10)** multiple choice questions located in the answer booklet you have been provided. *(Sample provided in this paper)*

© 2015 Australian and New Zealand College of Veterinary Scientists ABN 00 50 000894 208
This publication is copyright. Other than for the purposes of and subject to the conditions prescribed under the Copyright Act, no part of it may in any form or by any means (electronic, mechanical, microcopying, photocopying, recording or otherwise) be reproduced, stored in a retrieval system or transmitted without prior written permission. Enquiries should be addressed to the Australian and New Zealand College of Veterinary Scientists

Section A: **TWO** essay-type questions each worth 30 markstotal 60 marks

Section B: **FOUR** short-answer questions each worth 10 markstotal 40 marks

Section C: **TEN** multiple choice questions each worth 2 markstotal 20 marks

Paper 2: Veterinary Radiology (Small Animal)

SECTION A

Answer both questions in Section A

1. A seven-year-old Labrador is presented with vomiting of two days duration and a soft cough.

Answer **all** parts of this question:

- a) List **three (3)** differential diagnoses for vomiting in this patient. *(3 marks)*
- b) For **each** of the differentials listed in 1 a), describe the expected radiographic signs on plain abdominal radiographs, without oral contrast administration. *(15 marks)*

For the following questions, assume the respiratory signs observed in this dog are related to vomiting.

- c) List the radiographic projections of the thorax that you would recommend for this patient. Justify your recommendations. *(2 marks)*
- d) List **two (2)** differential diagnoses for the respiratory signs. *(2 marks)*
- e) For **each** of the differential diagnoses listed in 1 d), describe the expected radiographic signs. *(8 marks)*

Continued over page

2. A five-year-old cat is presented with sudden onset open mouth breathing.

Answer **all** parts of this question:

- a) Describe your approach to imaging this patient in a general practice setting. Both radiography and ultrasonography are available. *(4 marks)*

- b) List **four (4)** differential diagnoses for dyspnoea in this patient. *(4 marks)*

- c) For **each** differential diagnosis listed in 2 b), describe the imaging findings expected in **each** case and discuss how imaging may be used to distinguish between these differential diagnoses. *(16 marks)*

- d) Briefly discuss the use of advanced imaging in this patient. Include in your answer possible modalities, and the advantages of using advanced imaging. *(6 marks)*

Section B over page

SECTION B

Answer all four (4) questions in Section B

1. A nine-year-old entire male dog is presented with stranguria.

Answer **all** parts of this question:

- a) List **two (2)** differential diagnoses. (2 marks)
- b) For **both** of the differentials listed in 1 a), list the radiographic signs observed on plain radiographs. (6 marks)
- c) List **one (1)** additional imaging procedure that may be performed to further investigate this case. Justify why you choose this procedure. (2 marks)

2. A nine-year-old Red heeler is presented with collapse. On clinical examination you note pale mucous membranes, panting, jugular venous distention, dull chest sounds preventing auscultation of the heart, weak femoral pulses, and abdominal distention with a palpable fluid wave.

Answer **all** parts of this question:

- a) List **three (3)** differential diagnoses in this patient. (3 marks)
- b) Describe your approach to imaging this patient in a general practice setting. Both radiography and ultrasonography are available. (4 marks)
- c) For **one (1)** of the differentials listed in 2 a), describe the expected imaging findings. (3 marks)

Continued over page

3. Answer **all** parts of this question:

- a) List **four (4)** abnormalities which contribute to the syndrome of elbow dysplasia. *(2 marks)*
- b) Describe the radiographic appearance of **each** of these **four (4)** abnormalities listed in part 3 a). *(4 marks)*
- c) List the appropriate radiographic projections for investigation of a one-year-old Labrador retriever with lameness localised to the elbow. *(1 mark)*
- d) Describe the radiographic features used in elbow dysplasia screening and explain how these features are used to produce an elbow score. *(3 marks)*

4. Answer **all** parts of this question:

- a) Discuss what advice you would provide to a dog owner regarding imaging options for pregnancy investigation, and describe the expected imaging findings. *(6 marks)*
- b) Detail the imaging advice you would offer an owner of a bitch that was in season five weeks ago who wants to know the number of puppies to expect at delivery. *(2 marks)*
- c) Describe the expected radiographic findings in a bitch that is five weeks pregnant. *(2 marks)*

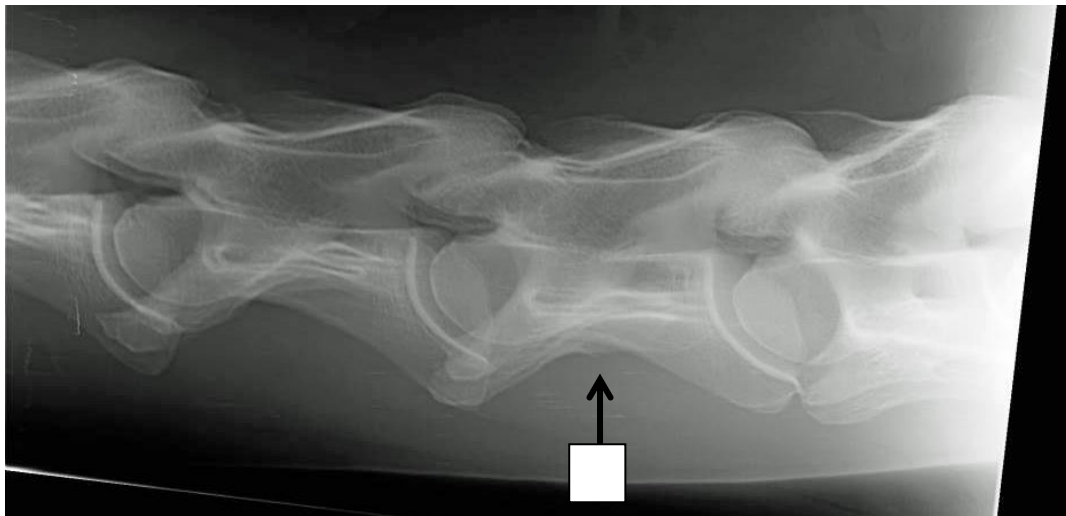
Section C continued in provided answer booklet

Paper 2: Veterinary Radiology (Small Animal)

Section C: Answer all ten (10) multiple choice questions in this section on printed pages 6 to 8 in this answer booklet.

Answer all ten (10) questions on the examination paper. This section is worth 20 marks. Each question is worth two (2) marks. Circle the letter corresponding to your chosen answer.

(10 multiple choice questions will be part of this examination located in a separate answer booklet that will be provided. Two examples for each paper have been made available.)



1. On the radiograph provided above the cervical vertebra labelled (x) is: (2 marks)
 - a) C4
 - b) C5
 - c) C6
 - d) C7

2. Which surface of the equine carpus will be projected in an unobstructed manner ('free projected') in a dorsolateral-palmaromedial radiograph? (2 marks)
 - a) Dorsomedial
 - b) Dorsolateral
 - c) Lateral
 - d) Dorsal

End of paper